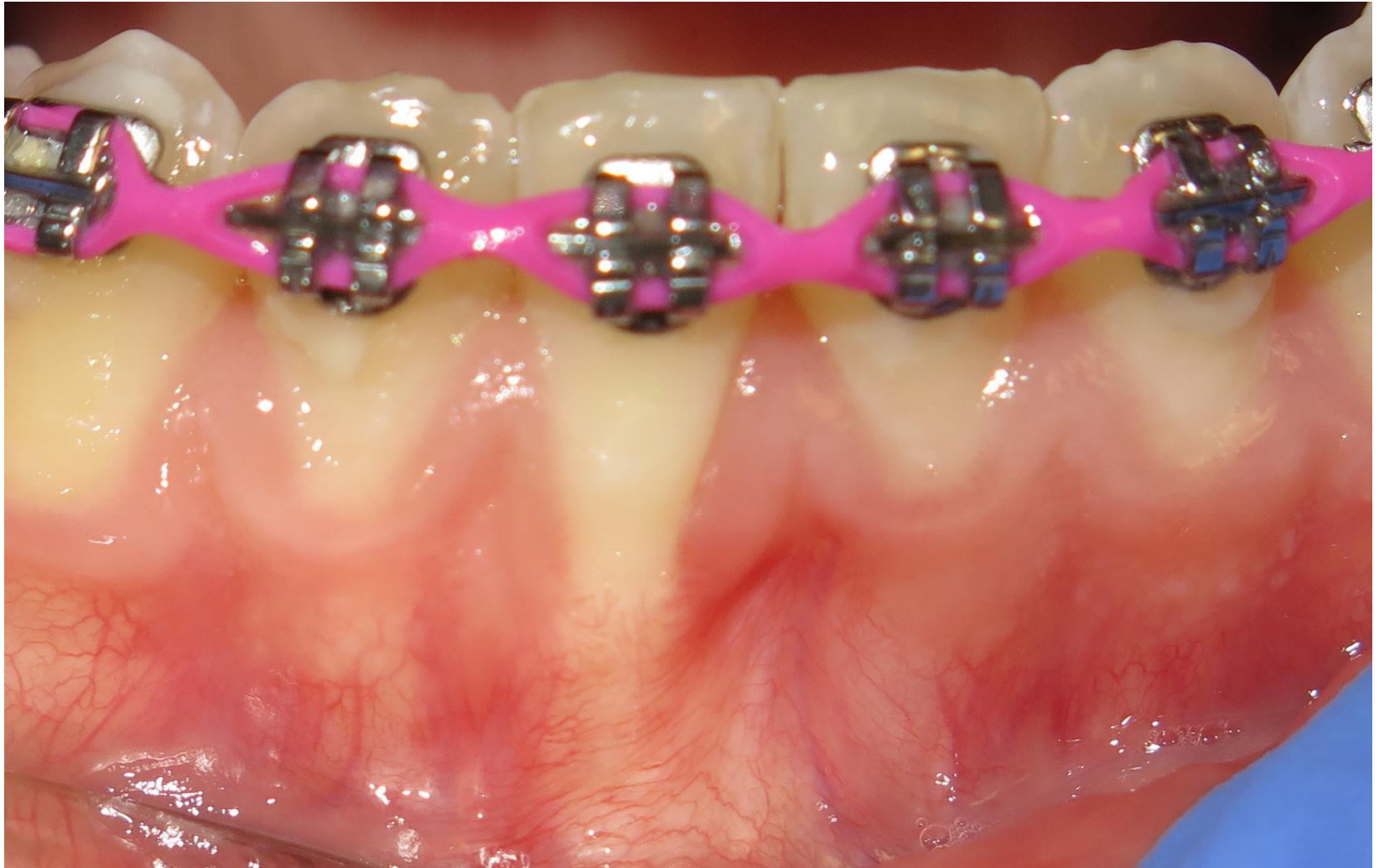
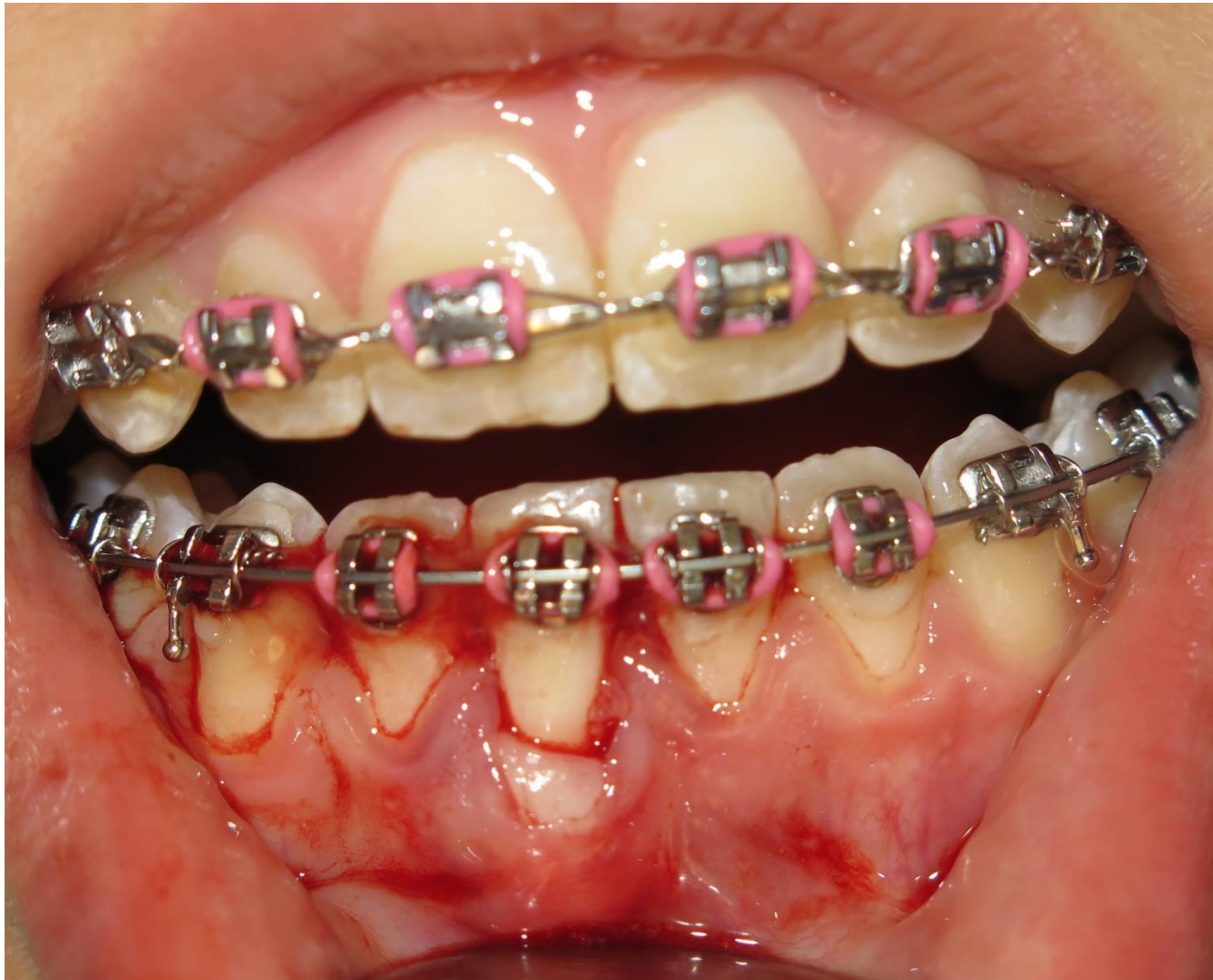
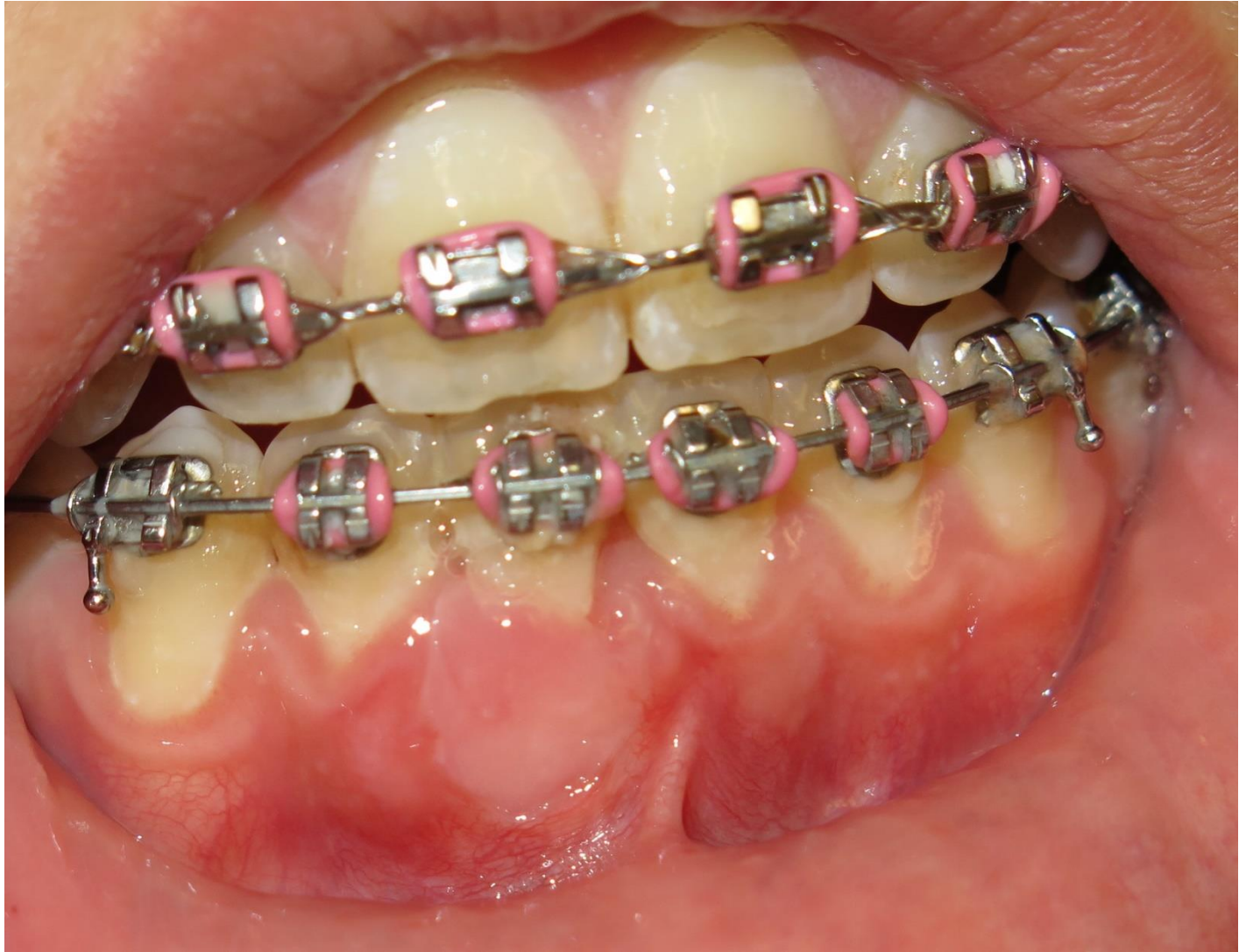Mandibular Anterior Mucogingival Defect



Minimally Invasive Procedure



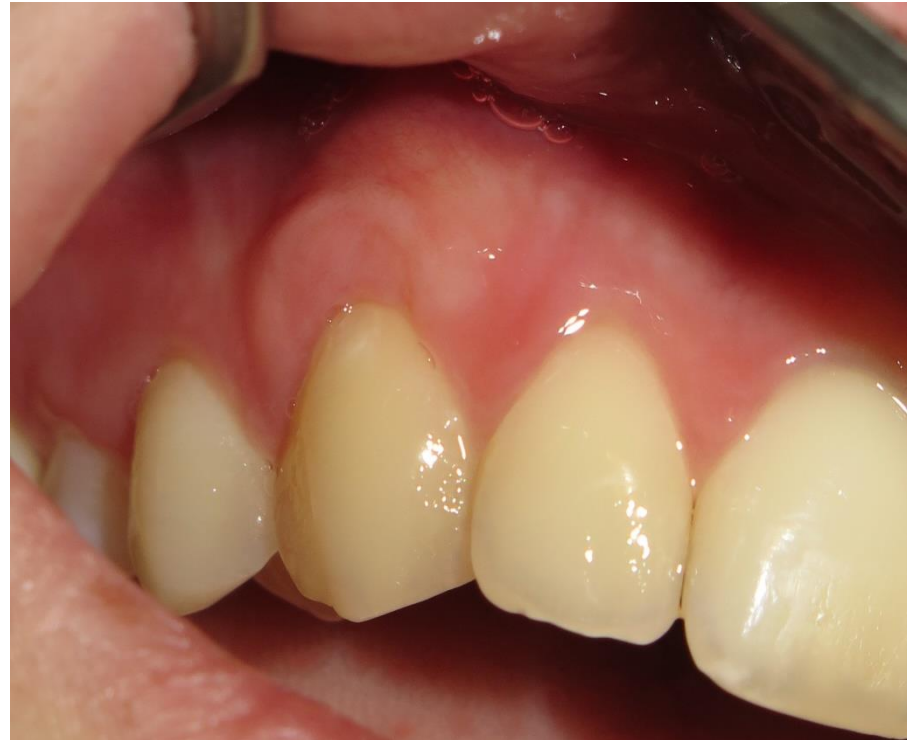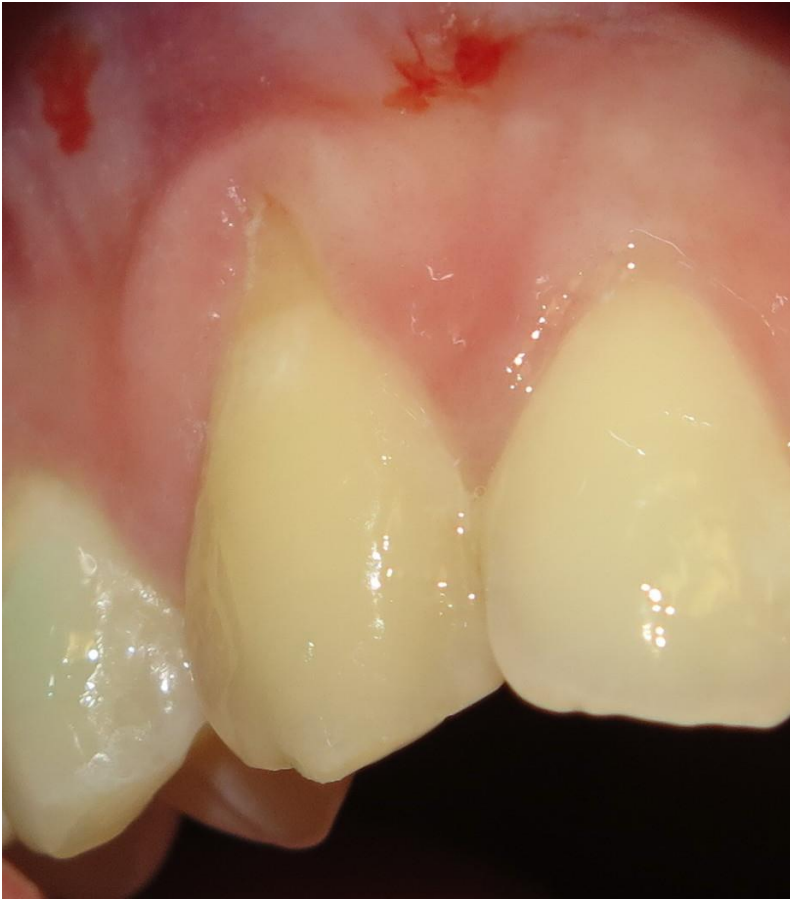
2 weeks healing



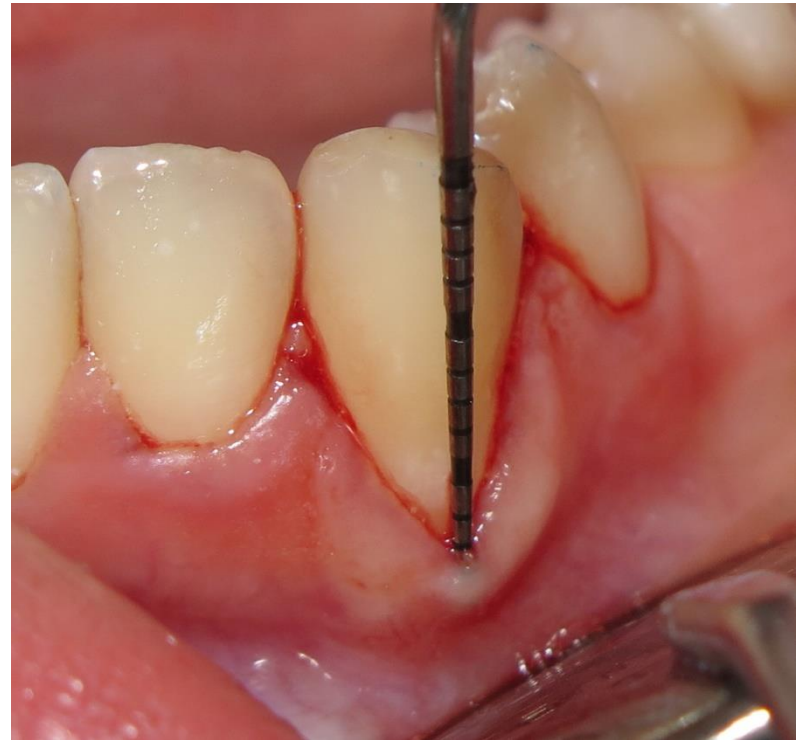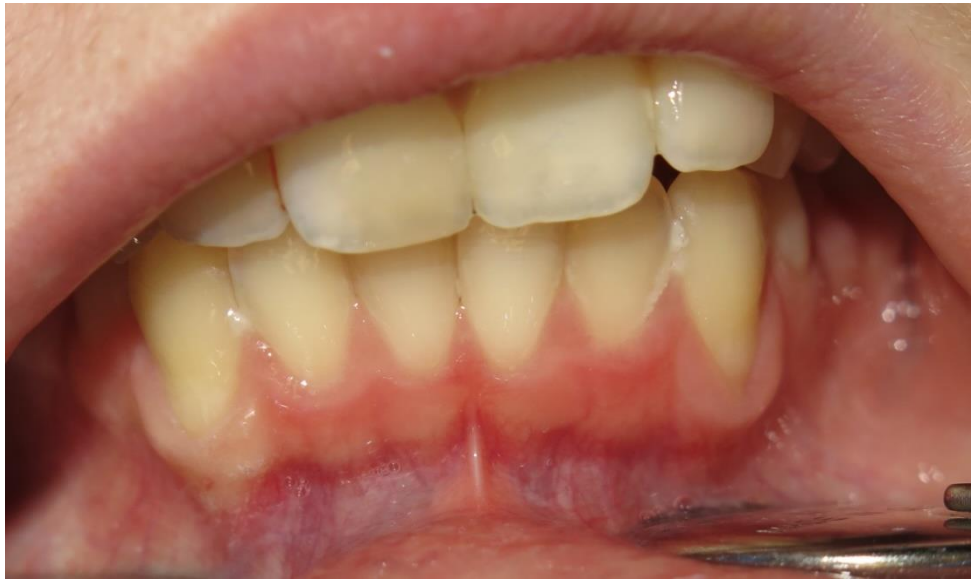#6 Mucogingival Defect

Before

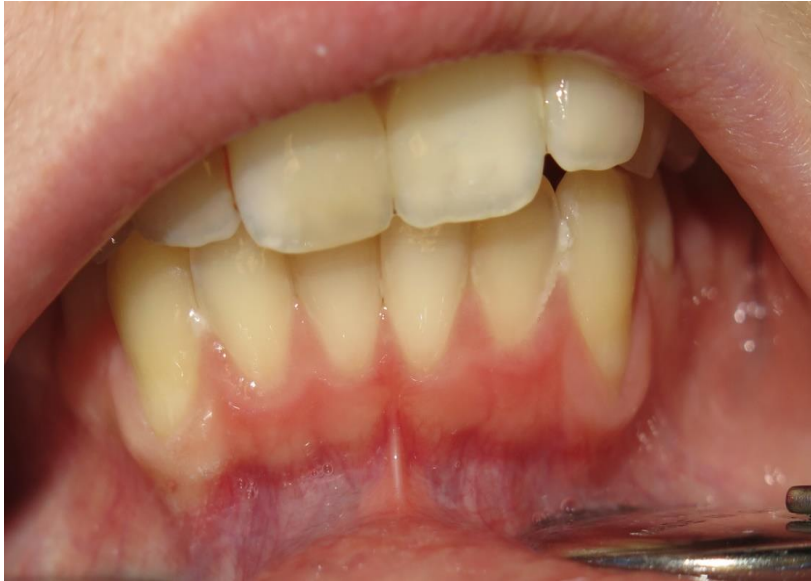After



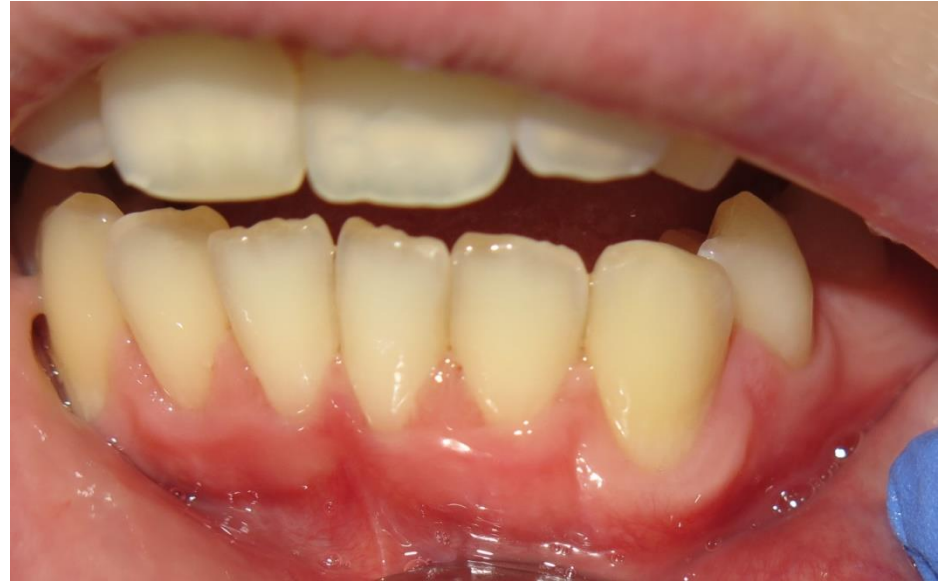#22 Mucogingival Defect



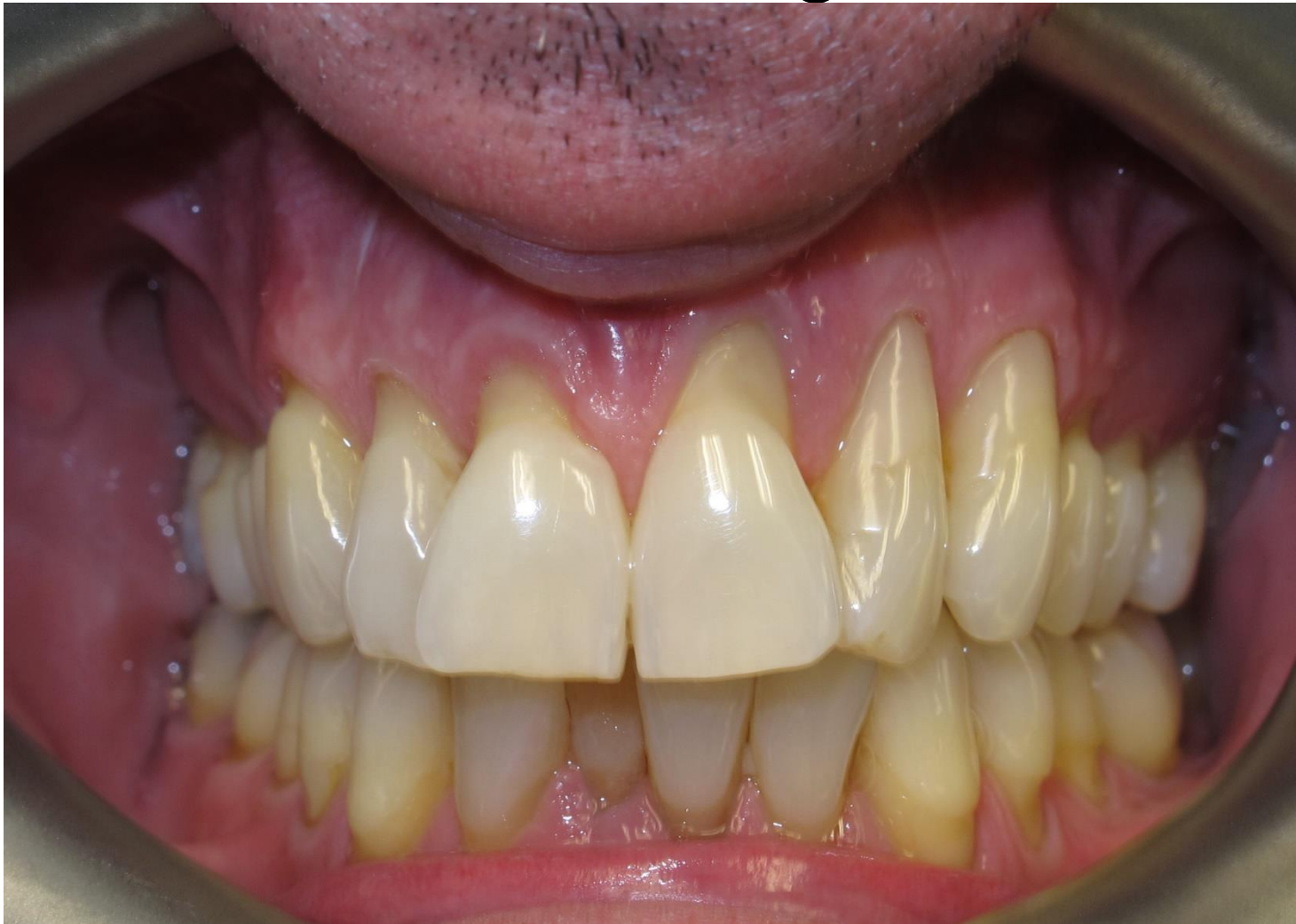Before

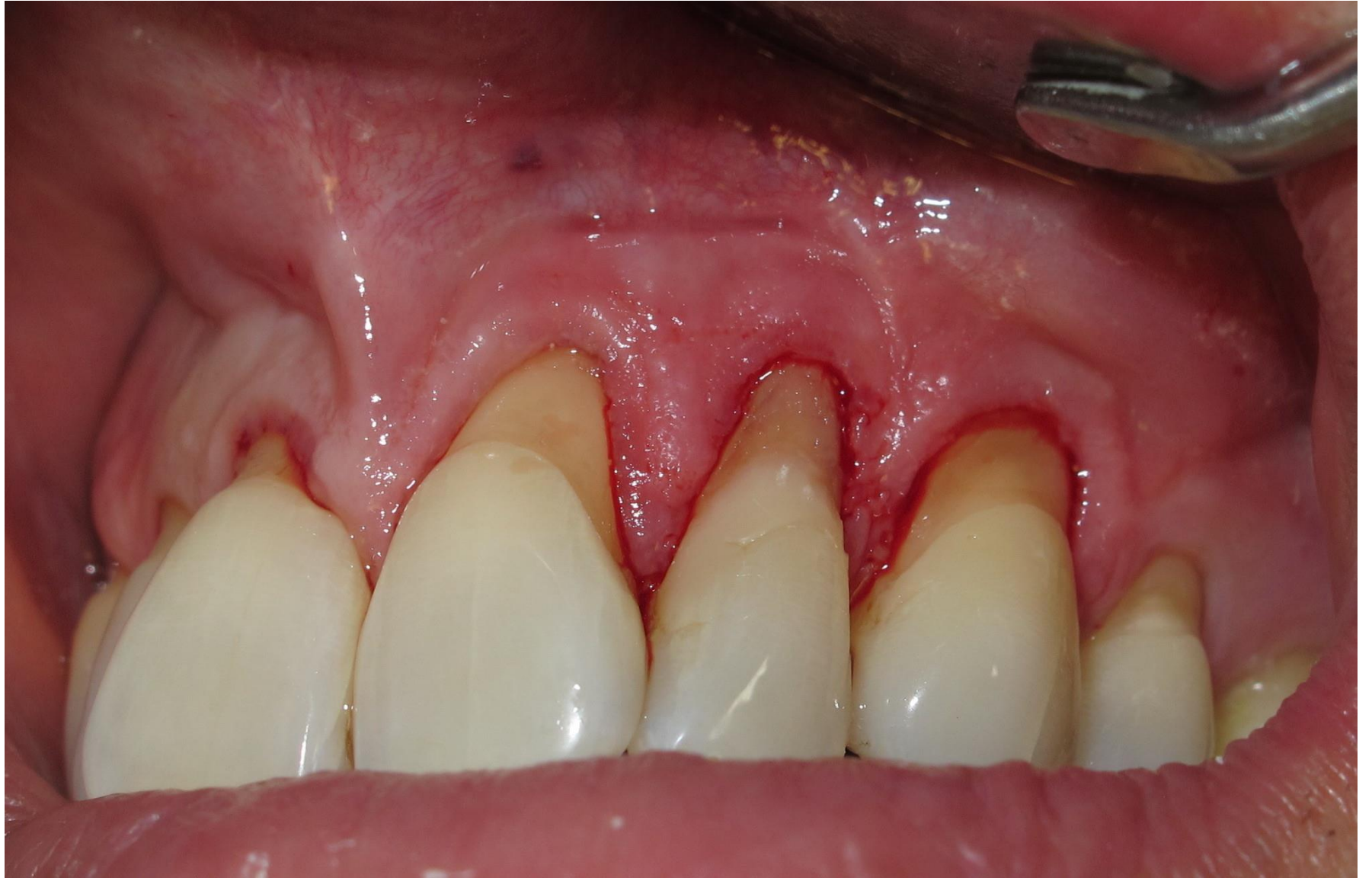

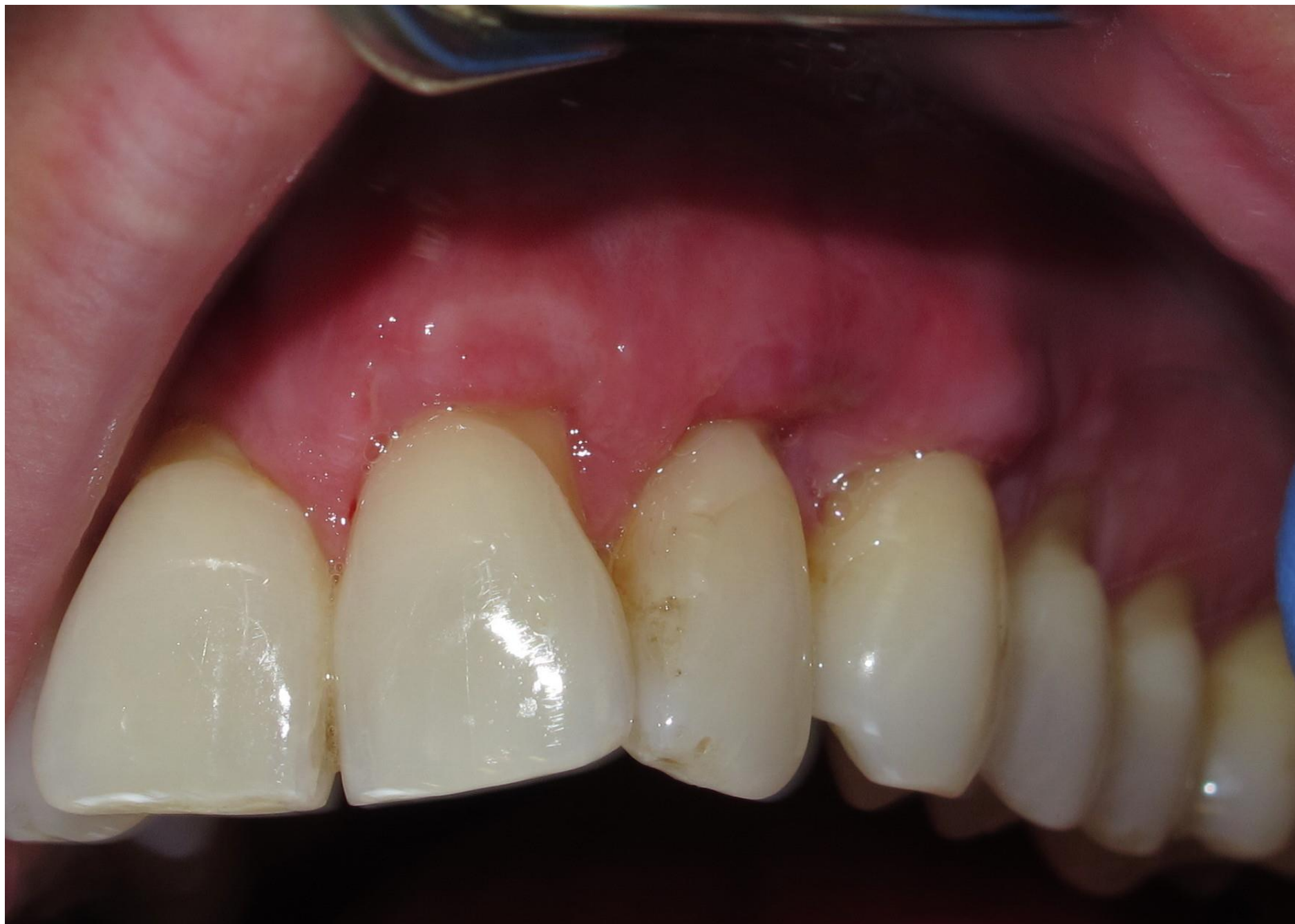After



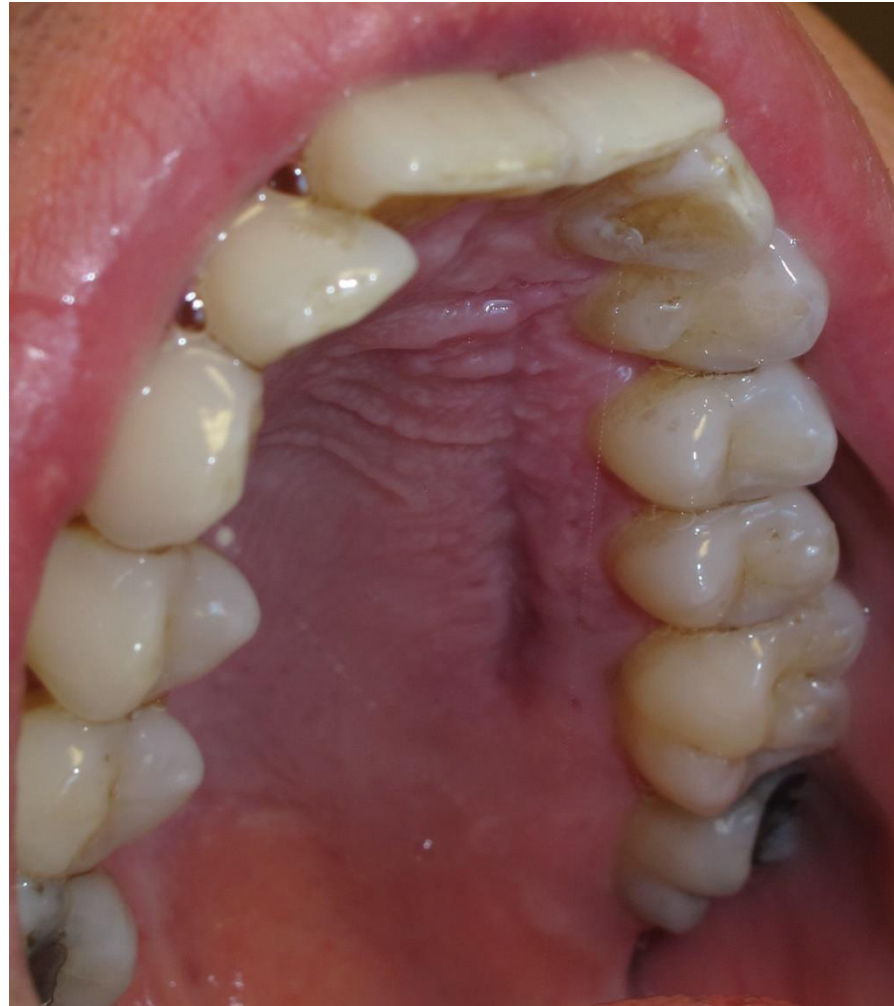Connective Tissue Graft with Debonding



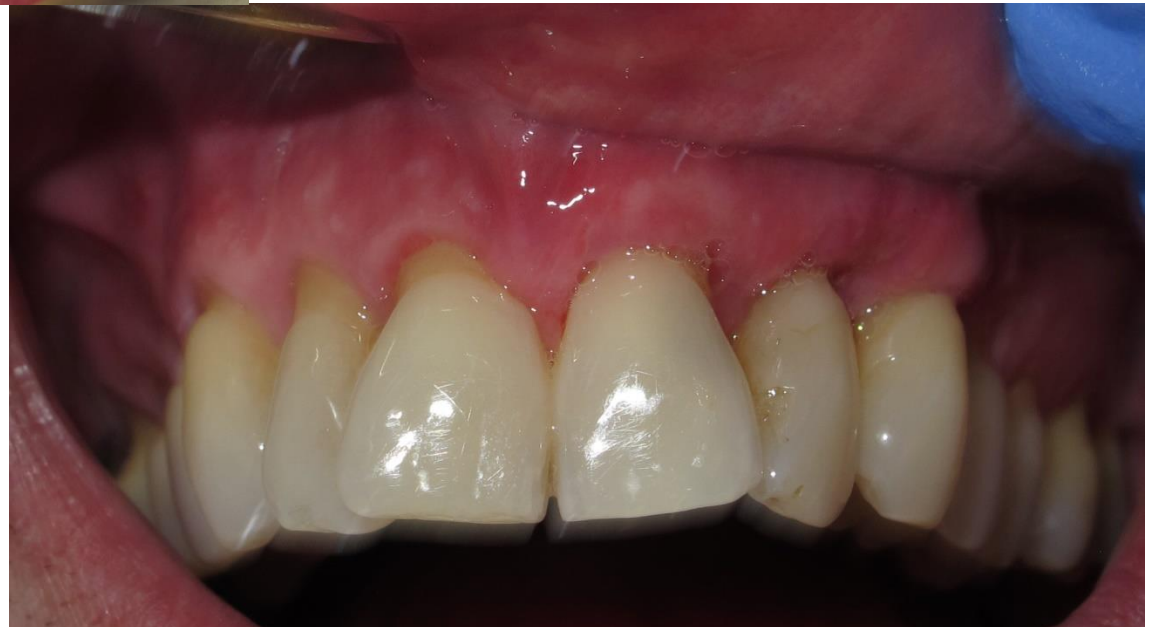
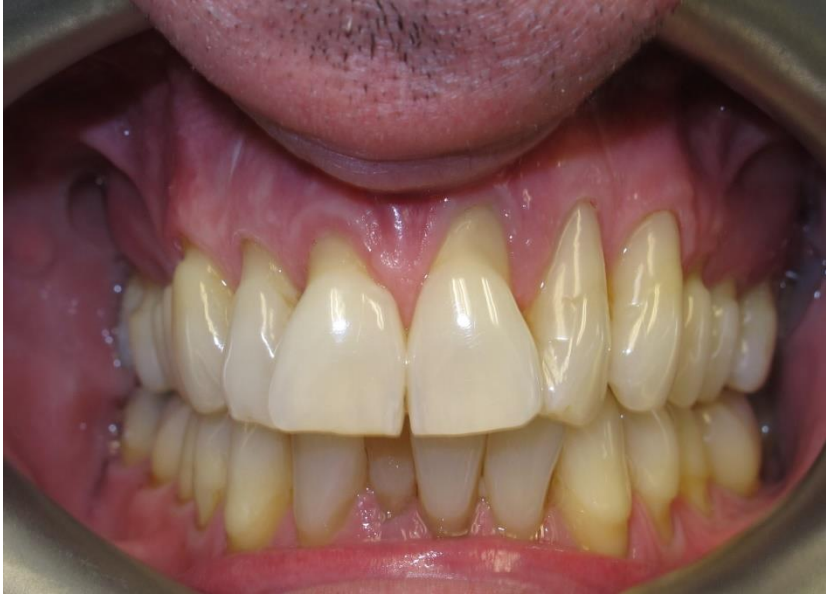


Donor Site Healing in 2 weeks



Before and After



For more information, please visit:
www.CTPerio.com